Klinische (Nofall)situationen

- nach schwieriger ZVK - Anlage
- Thoraxtrauma
- respiratorischer Insuffizenz
- hämodynamische Instabilität / Vd. Herzinsuffizienz
- schwieriges Weaning
- „weißes Rö-Thoraxbild"

DEGUM GK2 O. Vicent UKD

Darstellbare Pathologien

- Pneumothorax
- Pleuraerguss
- **Atelektasen**
- **Zwerchfellbewegung (Phrenikusparese)**
- Pleuraneoplasien
- **Konsolidierungen**
  - Pneumonie, Atelektase, Kontusion, ARDS
- Abszesse
- **interstitielle Flüssigkeit (Lungenödem, ARDS)**
- **Infarktareale (Lungenembolie)**

DEGUM GK2 O. Vicent UKD

DEGUM GK2 O. Vicent UKD

Standardisierter Untersuchungsgang

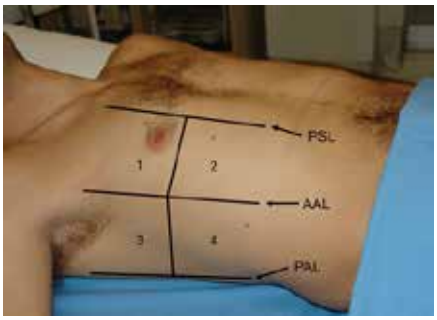

Volpicelli et al., Intensiv Care Med 2012; 38:577-591

DEGUM GK2 O. Vicent UKD

Diaphragm dysfunction assessed by ultrasonography: Influence on weaning from mechanical ventilation*

Won Young Kim, MD; Hee Jung Suh, RT; Sang-Bum Hong, MD, PhD; Younsuck Koh, MD, PhD, FCCM; Chae-Man Lim, MD, PhD, FCCM

Crit Care Med 2011 Vol. 39, No. 12

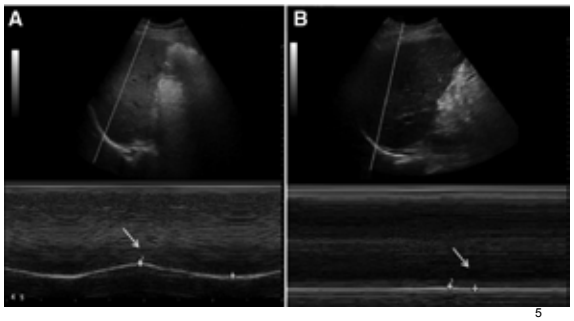

5

DEGUM GK2 O. Vicent UKD

Zwerchfellfunktion rechts

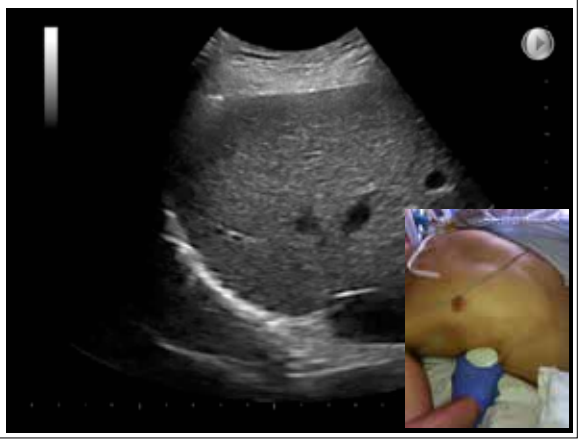

M - Mode zur Quantifizierung der Zwerchfellfunktion

DEGUM GK2 O. Vicent UKD

7

Zwerchfellparese links

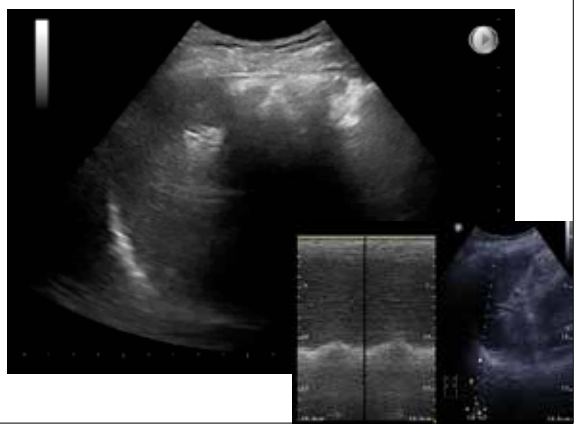

DEGUM GK2 O. Vicent UKD

peripherer Lungeninfarkt

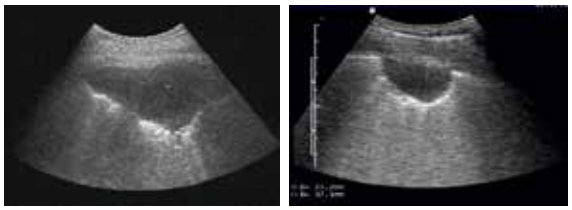

DEGUM GK2 O. Vicent UKD



Figure 1 Physical basis of lung ultrasound. The less air is in the lung, the easier is the detection of lung abnormalities by ultrasound.

Gargani Cardiovascular Ultrasound 2011, 9:6
http://www.cardiovascularultrasound.com/content/9/1/6 (27 February 2011)

10

DEGUM GK2 O. Vicent UKD

Interstitielle Flüssigkeit - B-Linien

Lichtenstein et al., Chest 2008; 134:117-25

Anzahl der B – Linien ICR korrelieren mit Stauung

(> 3 B – Linien) *Gargani L, Eur J Heart Failure 2008*

DEGUM GK2 O. Vicent UKD

Korrelation zwischen B-Linien und interstitieller Flüssigkeit

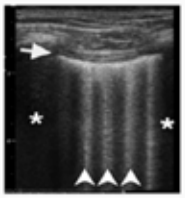

vereinzelt

Wenig interstitielle Flüssigkeit subpleural

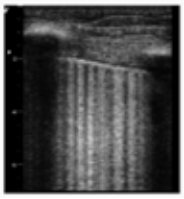

gehäuft (>3)

Viel interstitielle Flüssigkeit

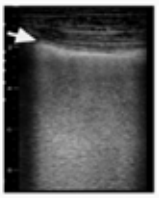

stark gehäuft und konfluierend („white lung")

Massiv Alveolär-Interstitielle Flüssigkeit

Via G et al., Minerva Anesthesiol 2012; 78:1282-96

DEGUM GK2 O. Vicent UKD

DEGUM GK2 O. Vicent UKD

B-Linien bei kardialem Lungenödem

Anzahl Korrelieren mit:

- proBNP
- **PaO2**
- Rö-Th
- EVLW
- PCWP
- Mortalität

Aber:

sensitiver und zeitiger

Jambrik Z et al., Am J Cardiol 2004;93:1265-70
Fagenholz PJ et al., Chest 2007;131:1013-8.
Gargani L et al., Eur J Heart Fail 2008;10:70-7
AgricolaE et al., Chest 2005;127:1690-5
Gargani L et al., Crit Care Med 2007;35:2769-74
Frassi F et al. J Cardiac Failure 2007.

DEGUM GK2 O. Vicent UKD

Anzahl der B-Linien: Korrelation mit ÜLZ (und pro-BNP)

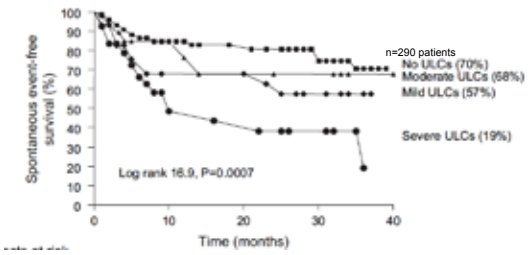

Frassi F et al. J Cardiac Failure 2007

15

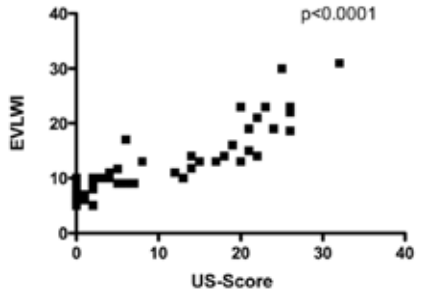

(Spearman's $r = 0.91$, $P < 0.0001$)

Enghard *et al. Critical Care* (2015) 19:36

16

DEGUM GK2 O. Vicent UKD

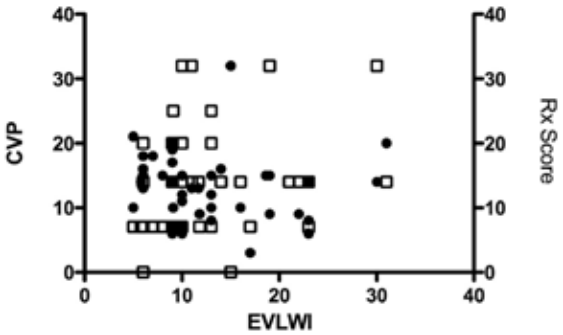

(Spearman's $r = 0.24$, $P = 0.11$) (Spearman's $r = 0.33$, and $P = 0.03$)

Enghard *et al. Critical Care* (2015) 19:36

17

DEGUM GK2 O. Vicent UKD

Differentialdiagnostik: Multiple B-Linien

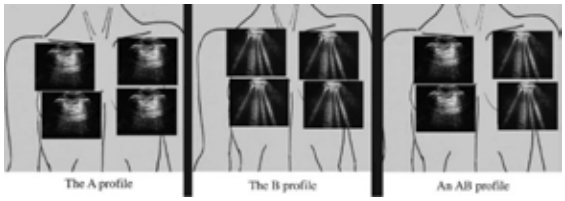

nicht vermehrt	beidseitig vermehrt	einseitig vermehrt
	- Lungenödem - ARDS	- Lungenkontusion - Pneumonie

Lichtenstein D et al., Chest 2008; 134:117-25

Lungenkonsolidierungen?

DEGUM GK2 O. Vicent UKD

DEGUM GK2 O. Vicent UKD

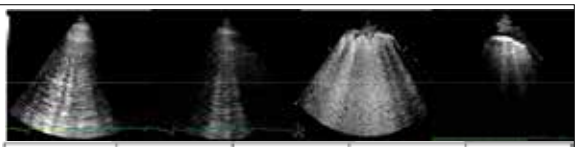

	Acute cardiogenic pulmonary edema	Chronic heart failure	ALI/ARDS	Pulmonary fibrosis
Clinical setting	acute	chronic	acute	chronic
B-lines number	****	*/**/***	****	*/**/***
B-lines distribution	multiple, diffuse, bilateral (white lung)	multiple, diffuse, bilateral, following decubitant regions (black and white lung)	non-homogeneous distribution, presence of spared areas	more frequently posterior at lung basis
Other LUS signs	pleural effusion	pleural effusion	pleural effusion, pleural alterations, parenchymal consolidations of various size	pleural thickening
Echocardiogram	abnormal	abnormal	likely normal	likely normal

ALI = acute lung injury; ARDS = acute respiratory distress syndrome; LUS = lung ultrasound.

19

DEGUM GK2 O. Vicent UKD

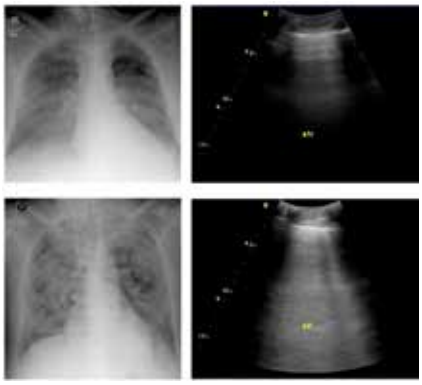

Enghard *et al. Critical Care* (2015) 19:36

20

DEGUM GK2 O. Vicent UKD

lung ultrasound score

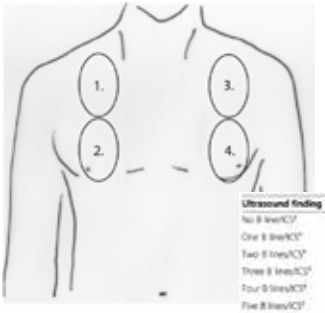

Ultrasound finding	Score
No B lines/ICS*	0
One B line/ICS*	1
Two B lines/ICS*	2
Three B lines/ICS*	3
Four B lines/ICS*	4
Five B lines/ICS*	5
Confluent B lines >50% ICS*	6
Confluent B lines >75% ICS*	7
Confluent B lines 100% ICS*	8

Enghard *et al. Critical Care* (2015) 19:36

21

	Clinical applications	References	Level of evidence
Acute dyspnea	Differential diagnosis of cardiogenic vs. noncardiogenic dyspnea	11, 12	☆
Chronic heart failure	Assessing new-growing congestion	6, 7, 8, 10, 22, 24	★
	Tailor therapy	13	☆
ALI/ARDS	– Early diagnosis – Differential diagnosis with cardiogenic pulmonary edema – Lung recruitment evaluation	9 30 42, 43	☆
HAPE	Pre-clinical detection	44, 45	☆
Dialysis	Lung fluid dynamic evaluation	32, 31	☆
Acute coronary syndromes	Prognostic stratification	34, 35	☆
Stress echo	Identification of exercise-induced myocardial stress failure, as sign of overt heart failure	33	☆

ALI = acute lung injury; ARDS = acute respiratory distress syndrome; HAPE = high altitude pulmonary edema
Green star = recommendation papers, endorsed by scientific commendies
Yellow star = original papers on TIA journals

Figure 7 Overview of the main clinical applications of lung ultrasound for the cardiologist

Gargani *Cardiovascular Ultrasound* 2011, **9**:6
http://www.cardiovascularultrasound.com/content/9/1/6 (27 February 2011)

pit falls

- Geräteeinstellung:
  - Verstärkung?
  - Tissue harmonic?
  - compound imaging?
- Betrachtung im klinischen Kontext und in Zusammenschau mit:
  - TTE, VCI,
  - Venendupplex

Lungenkonsolidierungen
– ARDS/Pneumonie/Kontusion –

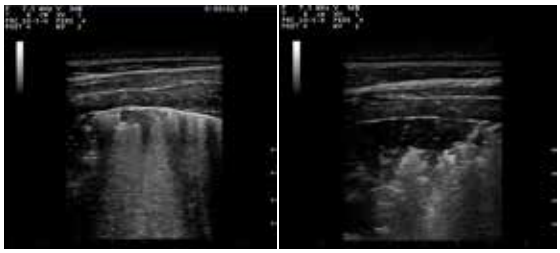

Dynamische Air Bronchogramme, irregelmäßig ausgerichtete B-Linien

DEGUM GK2 O. Vicent UKD

Lungenkontusion

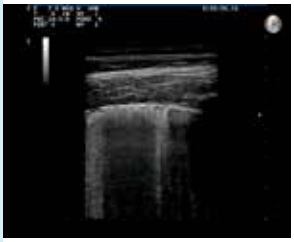

ARDS

DEGUM GK2 O. Vicent UKD

Recruitment

DEGUM GK2 O. Vicent UKD

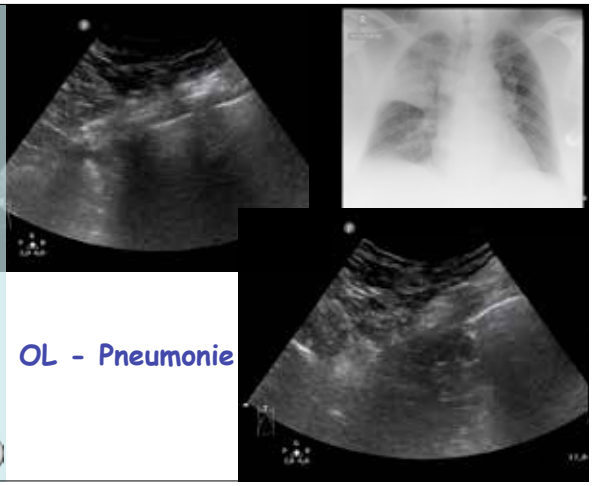

OL - Pneumonie

DEGUM GK2 O. Vicent UKD

Lungenkonsolidierungen
- Atelektase -

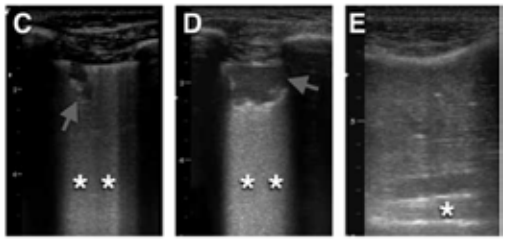

Kein Air Bronchogramm, regelmäßige wenige B-Linien, glatt begrenzt

DEGUM GK2 O. Vicent UKD

	Ausdehnung	B-Linien	Konso-lidierung
Atelektase	einseitig	normal	homogen
Pneumonie	meist einseitig	Vermehrt unregelmäßig	Inhomogen Dynamische Bronchogramme
ARDS	beidseitig	Vermehrt unregelmäßig	Inhomogen Dynamische Bronchogramme
Lungenödem	beidseitig	Vermehrt regelmäßig	keine
Kontusion	ein- oder beidseitig	Vermehrt Unregelmäßig fokal	Inhomogen Dynamische Bronchogramme

BLUE - Algorithmus

Lichtenstein DA, Chest. 2008 Jul;134(1):117-25.

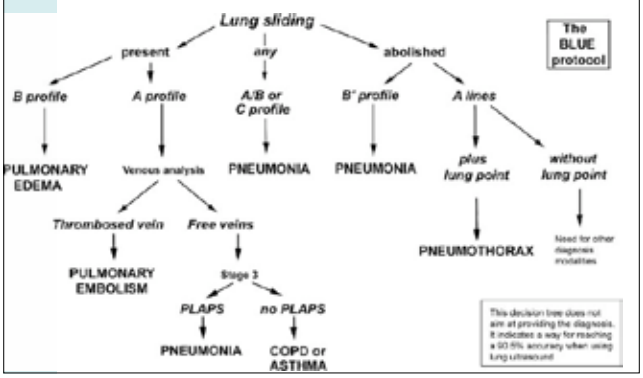

DEGUM GK2 O. Vicent UKD

Integrating lung ultrasound in the hemodynamic evaluation of acute circulatory failure (the fluid administration limited by lung sonography protocol)☆

Daniel Lichtenstein MD, PhD[a], Dimitrios Karakitsos MD, PhD[b,*]

Journal of Critical Care (2012) 27, 533.e11–533.e19

Heart and lung sliding analysis → *Obstructive shock (tamponade, embolism, pneumothorax)*

↓

Lung artifacts: B-profile → *Cardiogenic shock*

↓

Lung artifacts: A-profile

FALLS-protocol initiated → *Hypovolemic shock*

↓

Septic shock

31

DEGUM GK2 O. Vicent UKD
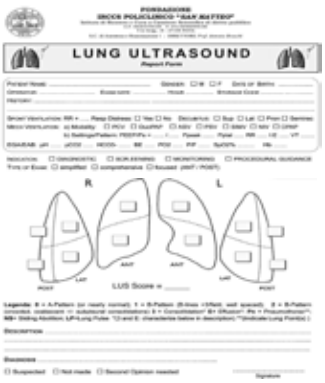
Dokumentation